

Colonoscopic Perforations

Vinay Rai, MD, FACS¹ Nitin Mishra, MD, FACS²

¹ Department of Surgery, University of New Mexico, Albuquerque, New Mexico

² Division of Colon and Rectal Surgery, Mayo Clinic College of Medicine, Phoenix, Arizona

Address for correspondence Vinay Rai, MD, FACS, Department of Surgery, University of New Mexico, Albuquerque, NM, 87131 (e-mail: vkrai@salud.unm.edu).

Clin Colon Rectal Surg 2018;31:41–46.

Abstract

Colonoscopy is the gold standard for colon cancer screening. It has led to a decrease in the incidence of colorectal cancer mortality. Colon perforation is a feared complication of this procedure with high morbidity and substantial mortality. Due to the high volume of colonoscopies performed, the absolute number of colonoscopic perforations is relatively high. It leads to a substantial cost to the patient and the health system. Understanding the mechanisms and the risk factors may help in preventing perforation. Traditionally, a laparotomy with creation of a stoma was used to address this complication. However, minimally invasive techniques such as laparoscopy and endoluminal repairs are being used more commonly now. More surgeons are favoring primary anastomosis (with or without a diverting loop ileostomy) than a Hartmann procedure.

Keywords

- ▶ colonoscopy
- ▶ perforation
- ▶ complication
- ▶ screening

Background and Incidence

Dr. William Wolff and Dr. Hiromi Shinya pioneered the development of the colonoscope in 1969.¹ The colonoscope is a flexible endoscope, which is used to visualize the lumen of the colon and the terminal ileum during a colonoscopy. Colonoscopy is used in the detection and prevention of colorectal cancers. It remains the gold standard for colorectal cancer screening. An estimated 14.2 million colonoscopies were performed in 2002.² Colon perforation is a well-known complication of colonoscopy. Cai et al estimated that 0.019 to 0.8% of diagnostic and 0.10 to 3% of therapeutic colonoscopies are associated with iatrogenic perforation.³ Colonoscopic perforation is associated with reported mortality of 5 to 7% and up to a third of patients end up with stomas.⁴ The incidence of iatrogenic perforations has increased with widespread acceptance of colonoscopic screening. In a 20-year review of the Nationwide Inpatient Sample (NIS), surgically treated gastrointestinal perforations were found to originate most often from the colon and rectum. The authors also noted a statistically significant increase in the proportion of iatrogenic perforations over the study period (1988–2007).⁵

Colonoscopic interventions include biopsy, snare polypectomy (with or without saline lift), endoscopic mucosal resection (EMR), and endoscopic submucosal dissection

(ESD). Most of these interventions can be done with or without the use of electrocautery. EMR and ESD are now being employed more commonly to resect sessile polyps or tumors, with a higher risk of perforation. In a meta-analysis comparing EMR versus ESD, the authors found the rate of perforation in the EMR group to be 1.4%, and that in the ESD group to be 5.7%.⁶

Mechanisms of Perforation

As depicted in ▶**Fig. 1**, colonoscopic perforations may be caused by one of the following mechanisms.^{7–9} The cause of injury often influences subsequent therapy decisions.

1. Mechanical trauma from manipulation of the colonoscope. This type of injury is usually associated with the largest perforations.⁸ Some of these injuries are immediately recognized due to bleeding or by visualizing intraperitoneal fat or viscera. Most of these perforations need immediate operations.
2. Barotrauma from excessive insufflation. These perforations most commonly occur in the cecum.
3. Perforation in the region of removed tissue by either polypectomy or EMR/ESD. This can be mechanical due

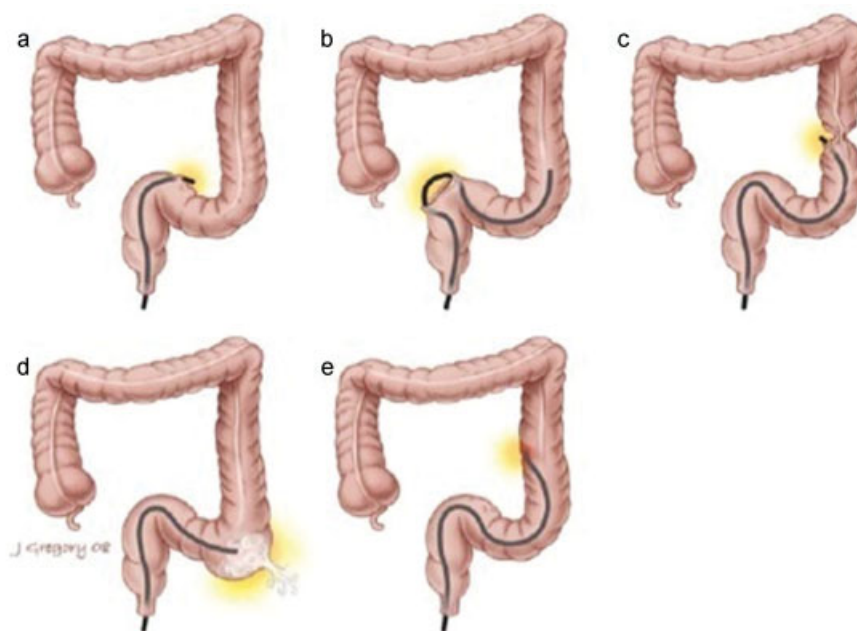


Fig. 1 Mechanisms of perforations during colonoscopy. (Reprinted with permission from Avgerinos et al.⁷)

to inappropriate use of biopsy instruments or from excessive use of thermal energy.

4. Thermal energy: Burn after coagulation of bleeding or after biopsy. These perforations usually present in a delayed fashion.
5. Miscellaneous: Dilatation of strictures or stent placement.

Site of Perforation

In a large retrospective study of 165 colonoscopic perforations reported by the Mayo clinic, the rectosigmoid colon was found to be the most frequent site of perforation (53%), followed by the cecum (24%), the ascending and transverse colon (9% each), and the remainder in the descending colon.⁴ Also, in a prior review by the same group, the rectosigmoid colon was reported to be the most common site of perforation (– Fig. 2).⁸

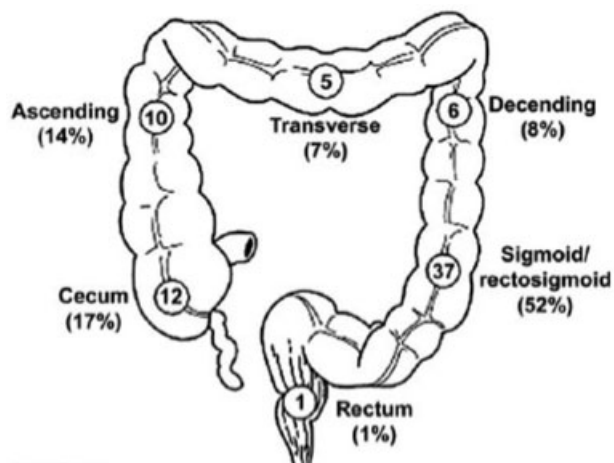


Fig. 2 Site of perforation. (Reprinted with permission from Iqbal et al.⁷).

Risk Factors

Several studies have investigated risk factors for colonoscopic perforations. In a retrospective analysis of risk factors using the Clinical Outcomes Research Initiative National Endoscopic Database, Bielawska et al found age greater than 75 years, increasing American Society of Anesthesia (ASA) class (representing higher comorbidity), female gender, procedures performed in a hospital setting, therapeutic colonoscopies, and resection of polyps greater than 10 mm to be significantly associated with increased risk of early perforation.¹⁰ Additionally, a large population-based study found obstruction as an indication for the colonoscopy to be significant risk factor for perforation.¹¹

Elderly patients with comorbidities have a higher chance of colonoscopic perforation. Perforation in this population can be life threatening. The endoscopist must remember that colonoscopy should be performed in these patients only if benefits outweigh the risks.^{10,12} Female gender also has been reported as a risk factor for perforation.^{10,13} Colonoscopy is often difficult due to fixed pelvic adhesions in females with a history of hysterectomy, with potentially increased risk of complications.¹⁴ Higher risk of colonoscopy-associated perforation is also seen in patients with inflammatory bowel disease (IBD) with severe disease seen at the time of endoscopy and on steroid treatment.¹⁵

Several studies have evaluated the role of the medical specialty of endoscopy and volume of endoscopy for the risk of colonoscopic perforations, with contradictory results.^{10,12,16,17} One study concluded that colonoscopy performed by nongastroenterologists increased the risk of early perforation.¹⁰ Other studies have not found similar association^{16,17} and one study found colonoscopy performed by surgeons to be safe and efficient whether performed for therapeutic or diagnostic purposes.¹⁷

It is not clear whether deep sedation increases the rate of perforation during colonoscopy. In a study looking at more than 100,000 colonoscopies, deep sedation with Propofol was associated with 2.5 times increased risk of perforation. The authors hypothesize that reduced perception of pain during deep sedation might explain the increase in perforation rates, as the endoscopist then advances the scope without patient feedback regarding exceedingly high pressure.¹⁸ However, Hansen et al believe that palpation of fixed colonic resistance and not pain is the principal indicator of impending perforation.¹⁹ Propofol use was not associated with increased risk of perforation in their study.¹⁹ Propofol use was not associated with increased risk in more than a million procedures in another study.¹⁰

Diagnosis

Some perforations are identified during the procedure when a full-thickness defect is seen in the colon wall or intraperitoneal fat or viscera are visualized. Other patients present later, most commonly within the first 24 hours.⁷ History, physical examination, and a high index of suspicion are important for making a diagnosis. Complaints of *persistent* abdominal pain and distension after a colonoscopy imply a perforation unless proven otherwise. Such patients need prompt evaluation for a colon perforation.²⁰ Abdominal plain films are diagnostic in most cases if they depict extraluminal free air. Computed tomography scans may be needed in patients with negative or equivocal radiographs.⁴ Apart from making the diagnosis, CT scans are also helpful in localizing the site of perforation in some cases.⁴

Aside from full-thickness perforation with intraperitoneal contamination, colonoscopy may produce other causes of postprocedure abdominal pain. Electrocoagulation injury to the colon wall during colonoscopy can induce a full-thickness burn known as coagulation syndrome. This full-thickness burn can lead to serosal inflammation and localized peritonitis.²¹ Hirasawa et al defined postpolypectomy syndrome (PPS) as a subset of coagulation syndrome resulting after polypectomy or EMR.²¹ Patients with PPS usually present with abdominal pain, fever, leukocytosis, elevated C reactive protein (CRP), or signs of localized peritonitis after use of electrocoagulation during colonoscopy. Imaging studies do not show any signs of perforation.²¹ The incidence of PPS is estimated to be 0.5 to 1.2%. Large lesion size and sessile lesions are risk factors for PPS.²² Cha et al also found hypertension to be a risk factor. They commented that endothelial dysfunction and atherosclerosis due to hypertension might contribute to the increased risk.²²

Recognition of PPS and coagulation syndrome is important as it resolves with nonoperative treatment in most patients.^{21,22} After ruling out perforation, patients are usually admitted for bowel rest and intravenous antibiotics until the symptoms subside.²¹ If a patient's symptoms worsen, reevaluation and imaging should be performed to rule out delayed perforation.²¹

Management

Early diagnosis and appropriate management mitigate the morbidity and the mortality associated with colonoscopic perforation.²⁰ However, the lack of large prospective randomized trials and specific guidelines makes it difficult to define optimal management of colonoscopic perforations.²³ In stable patients, treatment options range from nonoperative management to laparotomy with colon resection.

Nonoperative Management

Nonoperative management includes medical management and endoluminal repairs. Patients with asymptomatic perforations in the absence of generalized peritonitis or sepsis can be managed medically.²⁴ Pneumoperitoneum, per se, is not an indication for surgery. Castellví et al recommended medical management for cases with early diagnosis of perforation without generalized peritonitis, provided other conditions are met. Patients should be in good general condition, should have a good colon preparation, perforation should not be large enough to be noticed by the endoscopist, and it should not be due to a mechanical injury.²⁵ The intervention performed during the index colonoscopy may influence the need for immediate operative intervention. Some therapeutic procedures such as biopsy or snaring of small polyps or coagulation of small lesion may suggest smaller perforation more amenable to medical management, as opposed to EMR/ESD of a large lesion.⁴

Medical management usually involves hospital admission, bowel rest, intravenous hydration, and intravenous antibiotics.^{4,20} With the advent of newer endoscopic techniques and advanced methods for mucosal approximation, endoluminal repair of colonoscopic perforations is generating greater interest. In a review of 21 patients whose perforation was repaired endoluminally, the perforation was repaired with either endoscopic clips or endoscopic suturing. Two patients (out of 16) who underwent endosuturing required rescue procedures compared with all 5 patients who underwent clip closure, suggesting that mucosal clipping alone is not sufficient for full-thickness defects. This was a single-center, retrospective study with only 21 patients; however, it does demonstrate that endoluminal repair is feasible.²⁶

In carefully selected patients, morbidity following nonoperative treatment is lower compared with patients who have to undergo surgery.⁴ However, failure of the nonsurgical approach can lead to significant fecal contamination and a poor outcome.²³ Thus, these patients should be closely monitored. There are no large comparison studies evaluating outcomes following nonoperative and operative strategies, and individual surgeon's judgment remains the critical factor in deciding treatment.

Operative Management

The surgical options for treating colonoscopic perforations are primary repair of the perforation, resection of the perforated colon segment with primary anastomosis, resection of the perforated colon segment with primary

anastomosis along with protective proximal diversion (loop ileostomy or colostomy), and resection of the perforated colon segment with diversion (Hartmann's procedure).

In a large series of 165 operative repairs, primary repair or anastomosis could be performed safely in up to two-thirds of patients if the diagnosis was made within 24 hours. There was a higher rate of feculent peritonitis in patients presenting after 24 hours, making single-stage repair unlikely.⁴ Primary repair can be done for early diagnosed small perforations without significant contamination. Large perforations or avulsion injuries usually require resection. Also, colon resection should be considered if the segment of the perforated bowel has significant inflammation or contains pathology such as tumor or stricture.⁷ When resection is indicated, surgeons are leaning toward primary anastomosis in recent years. Diversion and staged operation is usually recommended for patients with delayed diagnosis leading to significant fecal contamination.

The operative approach can be laparoscopic or open laparotomy. Laparotomy has been the traditional surgical approach for colonic perforations. However, laparoscopy has a role in selected patients. Recent reports suggest that laparoscopy is a safe and effective alternative to laparotomy in a subset of patients with colonoscopic perforation.^{27,28} The principles of repair should be the same as for open surgery. In a recently published series of laparoscopic repair, primary repair was preferred in well-vascularized tissues when approximation of the edges of perforation could be performed without tension and did not lead to narrowing of the lumen. However, a formal resection with anastomosis of fresh, healthy colon ends was performed for large injuries. Finally, in cases with significant intraperitoneal contamination or injuries of the low rectum, staged repair was performed.²⁷ One study has postulated that laparoscopic repair has the potential to reduce medico-legal actions, as it is less traumatic than a laparotomy and recovery is expedited.²⁸ Laparoscopy is contraindicated in hemodynamically unstable patients. Any unstable patient should undergo an immediate laparotomy. Farley et al published a simple algorithm for the management of colonoscopic perforations²⁹ (→ Fig. 3).

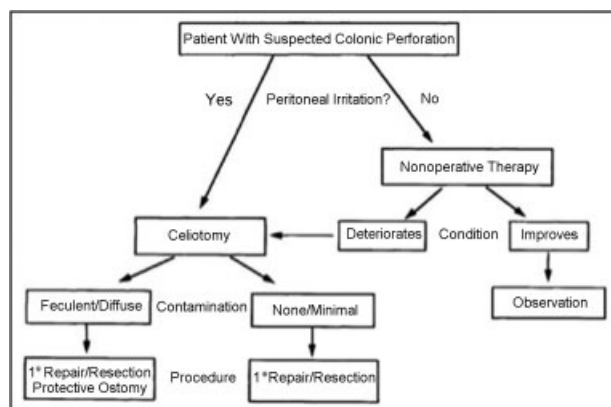


Fig. 3 Management algorithm for colonoscopic perforation. (Reprinted with permission from Farley et al.).

Outcomes

Colonoscopic perforation is associated with high morbidity and mortality. Teoh et al reported overall morbidity and mortality rates of 48.7 and 25.6%, respectively.³⁰ In another series of 165 patients, operative morbidity was 36%, with a mortality rate of 7%.⁴ The most common reported complication after surgery for colonoscopic perforation is wound infection and anastomotic leak is uncommon.^{4,30} In a series of 165 patients, the leak rate was less than 1%.⁴ Factors associated with poor patient outcomes include advanced age, delayed diagnosis, corticosteroid use, poor bowel preparation, mechanical blunt injury as the cause, antiplatelet therapy, and poor general condition (ASA score > 3).^{4,30}

Conclusion

Perforation during a colonoscopy has serious consequences. Despite a low rate, the absolute numbers of colonoscopic perforations are quite high due to the sheer magnitude of colonoscopies performed annually. The fact that a large proportion of colonoscopies are performed in the outpatient setting for screening purposes in otherwise healthy patients makes the consequences of this complication quite drastic and devastating for both the patient and the provider. This complication should be explicitly discussed with the patient when obtaining the informed consent for any colonoscopy. When performing a technically challenging colonoscopy, it is better to abort the procedure and use alternative diagnostic modalities than to risk perforating the colon. In a patient who is at an exceedingly high risk of colonoscopic perforation, it may be wise to obtain a virtual CT colonography instead of attempting a colonoscopy. All physicians performing colonoscopies should be well versed with the presentation and diagnosis of a perforation. Early diagnosis and appropriate management can reduce the morbidity and the mortality associated with colonoscopic perforations. In select cases, medical and endoscopic management can be used with good outcomes. Recently, laparoscopic approach had been used successfully in the operative management of colonoscopic perforations.

References

- 1 Wolff WI. Colonoscopy: history and development. *Am J Gastroenterol* 1989;84(09):1017–1025
- 2 Seeff LC, Richards TB, Shapiro JA, et al. How many endoscopies are performed for colorectal cancer screening? Results from CDC's survey of endoscopic capacity. *Gastroenterology* 2004;127(06):1670–1677
- 3 Cai SL, Chen T, Yao LQ, Zhong YS. Management of iatrogenic colorectal perforation: from surgery to endoscopy. *World J Gastrointest Endosc* 2015;7(08):819–823
- 4 Iqbal CW, Cullinane DC, Schiller HJ, Sawyer MD, Zietlow SP, Farley DR. Surgical management and outcomes of 165 colonoscopic perforations from a single institution. *Arch Surg* 2008;143(07):701–706, discussion 706–707
- 5 Mishra N, Roberts PL, Marcello PW, et al. Changing paradigms in acute care surgery: a shift to the hindgut. *Am Surg* 2014;80(01):76–80

- 6 Fujiya M, Tanaka K, Dokoshi T, et al. Efficacy and adverse events of EMR and endoscopic submucosal dissection for the treatment of colon neoplasms: a meta-analysis of studies comparing EMR and endoscopic submucosal dissection. *Gastrointest Endosc* 2015; 81(03):583–595
- 7 Avgerinos DV, Llaguna OH, Lo AY, Leitman IM. Evolving management of colonoscopic perforations. *J Gastrointest Surg* 2008;12(10):1783–1789
- 8 Iqbal CW, Chun YS, Farley DR. Colonoscopic perforations: a retrospective review. *J Gastrointest Surg* 2005;9(09):1229–1235, discussion 1236
- 9 Scott-Conner CEH. SpringerLink (Online service), Society of American Gastrointestinal Endoscopic Surgeons. The SAGES manual: fundamentals of laparoscopy, thoracoscopy, and GI endoscopy. 2nd ed. New York: Springer; 2006
- 10 Bielawska B, Day AG, Lieberman DA, Hookey LC. Risk factors for early colonoscopic perforation include non-gastroenterologist endoscopists: a multivariable analysis. *Clin Gastroenterol Hepatol* 2014;12(01):85–92
- 11 Arora G, Mannalithara A, Singh G, Gerson LB, Triadafilopoulos G. Risk of perforation from a colonoscopy in adults: a large population-based study. *Gastrointest Endosc* 2009;69(3, Pt 2):654–664
- 12 Chukmaitov A, Bradley CJ, Dahman B, Siangphoe U, Warren JL, Klabunde CN. Association of polypectomy techniques, endoscopist volume, and facility type with colonoscopy complications. *Gastrointest Endosc* 2013;77(03):436–446
- 13 Doran H, Marin IT, Iaciu M, Pătrașcu T. Iatrogenic perforations during colonoscopy. *Chirurgia (Bucur)* 2014;109(04):523–526
- 14 Garrett KA, Church J. History of hysterectomy: a significant problem for colonoscopists that is not present in patients who have had sigmoid colectomy. *Dis Colon Rectum* 2010;53(07):1055–1060
- 15 Navaneethan U, Kochhar G, Phull H, et al. Severe disease on endoscopy and steroid use increase the risk for bowel perforation during colonoscopy in inflammatory bowel disease patients. *J Crohn's Colitis* 2012;6(04):470–475
- 16 Lohsiriwat V. Colonoscopic perforation: incidence, risk factors, management and outcome. *World J Gastroenterol* 2010;16(04):425–430
- 17 Wexner SD, Forde KA, Sellers G, et al. How well can surgeons perform colonoscopy? *Surg Endosc* 1998;12(12):1410–1414
- 18 Adeyemo A, Bannazadeh M, Riggs T, Shellnut J, Barkel D, Wasvary H. Does sedation type affect colonoscopy perforation rates? *Dis Colon Rectum* 2014;57(01):110–114
- 19 Hansen JJ, Ulmer BJ, Rex DK. Technical performance of colonoscopy in patients sedated with nurse-administered propofol. *Am J Gastroenterol* 2004;99(01):52–56
- 20 Kim HH, Kye BH, Kim HJ, Cho HM. Prompt management is most important for colonic perforation after colonoscopy. *Ann Coloproctol* 2014;30(05):228–231
- 21 Hirasawa K, Sato C, Makazu M, et al. Coagulation syndrome: Delayed perforation after colorectal endoscopic treatments. *World J Gastrointest Endosc* 2015;7(12):1055–1061
- 22 Cha JM, Lim KS, Lee SH, et al. Clinical outcomes and risk factors of post-polypectomy coagulation syndrome: a multicenter, retrospective, case-control study. *Endoscopy* 2013; 45(03):202–207
- 23 An SB, Shin DW, Kim JY, Park SG, Lee BH, Kim JW. Decision-making in the management of colonoscopic perforation: a multicentre retrospective study. *Surg Endosc* 2016;30(07):2914–2921
- 24 Damore LJ II, Rantis PC, Vernava AM III, Longo WE. Colonoscopic perforations. Etiology, diagnosis, and management. *Dis Colon Rectum* 1996;39(11):1308–1314
- 25 Castellví J, Pi F, Sueiras A, et al. Colonoscopic perforation: useful parameters for early diagnosis and conservative treatment. *Int J Colorectal Dis* 2011;26(09):1183–1190
- 26 Kantsevov SV, Bitner M, Hajiyeva G, et al. Endoscopic management of colonic perforations: clips versus suturing closure (with videos). *Gastrointest Endosc* 2016;84(03):487–493
- 27 Makarawo TP, Damadi A, Mittal VK, Itawi E, Rana G. Colonoscopic perforation management by laparoendoscopy: an algorithm. *JSLS* 2014;18(01):20–27
- 28 Rotholtz NA, Laporte M, Lencinas S, Bun M, Canelas A, Mezzadri N. Laparoscopic approach to colonic perforation due to colonoscopy. *World J Surg* 2010;34(08):1949–1953
- 29 Farley DR, Bannon MP, Zietlow SP, Pemberton JH, Ilstrup DM, Larson DR. Management of colonoscopic perforations. *Mayo Clin Proc* 1997;72(08):729–733
- 30 Teoh AY, Poon CM, Lee JF, et al. Outcomes and predictors of mortality and stoma formation in surgical management of colonoscopic perforations: a multicenter review. *Arch Surg* 2009; 144(01):9–13